

CASE REPORT

Open Access

The silent sinus syndrome: protean manifestations of a rare upper respiratory disorder revisited

Denisse E Guillen¹, Paulette M Pinargote¹ and Juan C Guarderas^{2*}

Abstract

Silent Sinus Syndrome (SSS) is known to be a rare clinical condition, characterized by spontaneous and progressive enophthalmos and hypoglobus associated with atelectasis of the maxillary sinus and alteration of the orbital floor. Most of the patients with this syndrome present with ophthalmological complaints without any nasal sinus symptoms, and it typically has a painless course and slow development, ergo the term "silent." Here we present a case report of a patient with occasional coughing spells as the presenting symptom of Silent Sinus Syndrome, which has not been previously described in the literature. The CT scan findings suggested chronic rhinosinusitis. The radiological findings were suggestive of maxillary sinus hypoplasia, with evidence of maxillary sinus atelectasis. Awareness of this syndrome is important for specialists who work with nasal sinus disease, since its management is different than chronic rhinosinusitis.

Background

Silent Sinus Syndrome (SSS) is known as a rare clinical condition, characterized by spontaneous and progressive enophthalmos and hypoglobus [1] associated with atelectasis of the maxillary sinus and alteration of the orbital floor. This syndrome was first described in 1964 by Montgomery [2], but it was named Silent Sinus Syndrome in 1994 by Soparkar et al. [3]. Most of the patients with this syndrome present with ophthalmological complaints without any nasal sinus symptoms, and it typically has a painless course [3] and slow development, ergo the term "silent." We review the concepts of SSS and review the two most likely mechanisms of this condition.

It's very common that these patients first present to ophthalmology [4] due to the syndrome's typical constellation of progressive enophthalmos and hypoglobus. SSS typically presents unilaterally [5], with a slight predominance for presenting on the right maxillary sinus (57%) [6], and its development is gradual and progressive. The physical exam shows some degree of orbital asymmetry, with deepening of the superior orbital sulcus and the consequent hypoglobus. Some other ophthalmological signs can be eyelid retraction, lid lag,

and lagophthalmos [7]. Occasionally, exophthalmos of the contralateral uninvolved eye is reported [8]. Although the visual function is typically unaffected, a few patients have reported alterations in ocular motility or muscle imbalance producing diplopia [9].

Radiographic findings

The computed tomography (CT) scans of the nose and paranasal sinuses typically show opacification of the maxillary sinus and inferior bowing of the orbital floor [10]. The sinus can be developed or hypoplastic but is opacified, and the infundibulum is obstructed. This obstruction is usually caused by a lateral retraction of the uncinate process with its apposition in the inferiomedial part of the orbit [11]. Sanchez et al. described an image of a "pseudo-pneumo-orbit" that can also be seen due to air trapped under the upper eyelid [12]. Both CT and magnetic resonance imaging (MRI) scans allow physicians to perform a SSS diagnosis, but CT scans are considered the gold standard diagnostic method because they provide a better view of the anatomical changes of SSS that are needed for its diagnosis and for differentiation from other conditions [13].

Management and treatment

Treatment should address the obstruction of the sinus and the resultant ocular consequences. Treatment consists of re-aeration of the atelectatic sinus by endoscopic

* Correspondence: Guarderas.juan@mayo.edu

²Department of Otorhinolaryngology, Mayo Clinic, 4500 San Pablo Road, Jacksonville, FL 32224, USA

Full list of author information is available at the end of the article

sinus surgery. All authors agree that sinus pathology should be treated endoscopically as the first step of the treatment [14].

Limited antrostomy typically results in a release of negative sinus pressure and re-expansion of the collapsed cavity leading to reduction of enophthalmus [15]. A wide antrostomy prevents future reobstructions, and good re-aeration of the sinus helps to avoid recurrent enophthalmos [16].

Timing for management of the orbital floor is still under debate. As suggested by some authors, orbital floor reconstruction must be performed simultaneously with sinus treatment [17]. Other authors think that only drainage of the sinus should be enough [18]. According to Cardesin et al., the need for orbital floor repair depends on the severity of the diplopia, the degree of the cosmetic alterations, and the postsurgical evaluation of the sinus [19].

Case presentation

A 66-year-old gentleman, non-smoker, with no known allergies or significant respiratory medical history, presented to the Allergy Medicine service with a chief complaint of cough. He describes that he suffered a respiratory infection approximately three months prior to the visit. After it was treated, the majority of symptoms resolved, but the cough and coughing spells persisted with post-nasal drainage and clearing of the throat. The CT scan revealed an asymmetrically smaller and completely opacified left maxillary sinus with left-sided periosteal thickening as well as lateral bowing/bone remodeling of the uncinate process. The opacified left maxillary sinus had hyperdensities which could represent chronic dense secretions (Figure 1). The left ostiomeatal complex was occluded (Figure 2). The initial diagnosis was chronic sinusitis. He was prescribed antibiotics for 10 days, was advised to have a new sinus CT scan, and was referred to otorhinolaryngology.

Two months later when the patient presented to otorhinolaryngology for follow-up, there had been no clinical changes. The physical exam showed some asymmetry of both eyes with mild hypoglobus of the left eye. His nose had a moderate anterior septal deformity to the left with mucoid drainage. He was unaware of vision changes, but testing demonstrated double vision when looking to the extreme right. The rest of the exam was normal.

The new sinus CT scan showed no significant change. The interpretation was a persistent opacified hypoplastic left maxillary sinus with obstructed left ostiomeatal unit with lateralization of the uncinate process. The pattern was consistent with type 2 maxillary sinus hypoplasia. A sino-nasal endoscopy confirmed the previous imaging findings.

The patient underwent a turbinoplasty and endoscopic sinus surgery (antrostomy) to address the total opacification of his left maxillary sinus. The nasal sinus

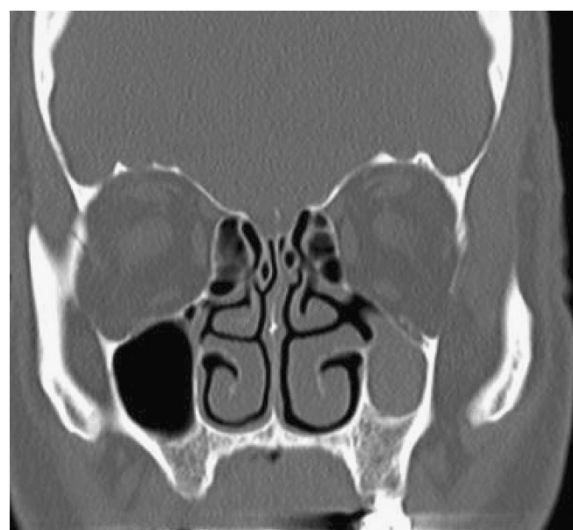


Figure 1 Examination reveals an asymmetrically smaller and completely opacified left maxillary sinus with left-sided periosteal thickening, as well as lateral bowing/bone remodeling of the uncinate process.

symptoms and cough resolved after the procedure. Correction of the enophthalmos was not necessary.

Discussion

SSS has two main theorized mechanisms: maxillary sinus atelectasis (MSA)—which could be idiopathic, post-traumatic, or post-surgery—or maxillary sinus hypoplasia (MSH).

Chronic rhinosinusitis (CRS) has a prevalence of 13.4% in adults older than 18 years of age, according to a national health survey conducted in 2008 [20]. The causes

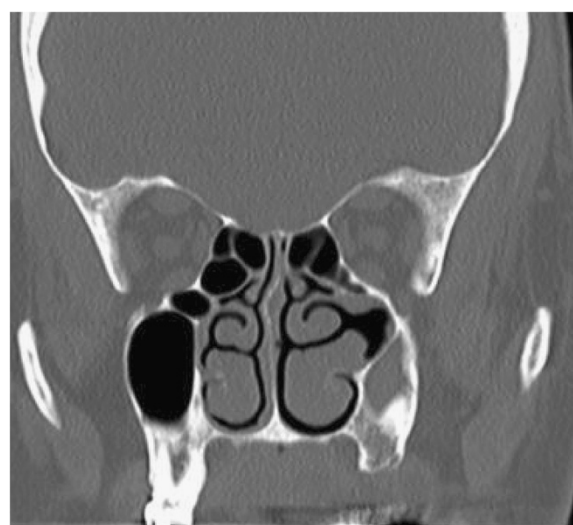

Figure 2 The left maxillary sinus is smaller and opacified. The middle meatus space is wide and the medial wall of the sinus is lateralized with contact with the lateral wall of the maxillary sinus.

and classification of CRS have recently been reviewed by Hamilos [21]. Causes of CRS are frequently anatomical and include septal deformity, Haller's cells, paradoxical middle turbinate, and agger nasi cell. A hypoplastic maxillary sinus, an atelectatic maxillary sinus, and silent sinus syndrome are infrequently recognized causes of CRS. A description of these entities is reviewed in this paper.

Maxillary sinus hypoplasia (MSH) is an infrequent congenital anomaly that Bolger et al. [22] noted in 10.4% of 202 consecutive CT scans reviewed. MSH has been classified as type 1 when there is a normal uncinata process and a defined infundibular passage. Type 2 has a hypoplastic or absent uncinata process with an opacified affected sinus, and type 3 has an absent uncinata process and profound hypoplasia of the sinus. This classification has been supported by Erden (Table 1) [23].

Chronic maxillary atelectasis (CMA) is a term that describes a persistent decrease in the sinus volume from inwardly bowing antral walls [24]. In a 1997 study that spanned over ten years at the Massachusetts Eye and Ear Infirmary, 22 individuals were diagnosed with CMA, and their literature review found 25 additional individuals who met their criteria. Their criteria included: sinus opacification on CT scans or X-rays lasting more than 3 months and/or tenacious mucus secretions filling the antrum in addition to lateral displacement of the medial infundibular wall (MIW).

CMA, in reference to the Massachusetts Eye and Ear work, was differentiated in 3 stages based on the anatomical changes: Stage 1 (membranous deformity) where there is a lateralization of the maxillary fontanel, Stage 2 (bone deformity) where there is inward bowing of one or more osseous walls of the maxillary antrum, and Stage 3 (clinical deformity) where enophthalmus, hypoglobus, and/or midfacial deformity is noted (Table 2) [24].

In this series of 22 patients, 19 had some degree of sinus symptoms and five had findings of hypoglobus.

Silent sinus syndrome is a very uncommon clinical entity [25]. The pathophysiology of this syndrome remains unanswered in part because there is rarely a pre-symptomatic CT scan that can be used to review the stages of the process. A hypothesis for the pathophysiology is that hypoventilation of the sinus due to

Table 2 Stages of chronic maxillary atelectasis [24]

	Characteristics
Stage 1	Membranous deformity where there is lateralization of the maxillary fontanel
Stage 2	Bone deformity where there is inward bowing of one or more osseous walls of the maxillary antrum
Stage 3	Clinical deformity with enophthalmus, hypoglobus, and/or midfacial deformity is noted.

obstruction of the osteomeatal unit [26] creates a negative pressure [27] that leads to atelectasis [28] of the sinus with a downward displacement of the orbital floor [29]. There is disagreement over whether the obstruction of the osteomeatal unit (OMU) is caused by hypoplasia and/or if there are any cases where a normally developed sinus due to trauma, surgery, or other cause can be obstructed and consequently develop atelectasis and SSS.

Conclusion

In this paper, we have reviewed the clinical and radiological presentation of SSS. Patients with SSS most often present to ophthalmology practices due to complaints of facial or ocular asymmetry such as hypoglobus or enophthalmos with little or no nasal sinus symptoms [30]. However, these patients may occasionally also present to otorhinolaryngology or allergy medicine, with nasal sinus symptoms suggestive of sinusitis. The mechanism of the development of SSS has been thought to be atelectasis of the maxillary sinus with or without the presence of maxillary sinus hypoplasia, especially in type 2.

Our patient presented to otolaryngology and allergy medicine for evaluation of a chief complaint of chronic cough with occasional coughing spells which have not been described in the literature as a form of presentation of Silent Sinus Syndrome. The CT scan findings suggested CRS. The radiological findings were suggestive of MSH, and there was evidence of MSA.

The differentiation of SSS from CRS is important since sinus surgery is the procedure of choice and clear knowledge of this anatomy is very important for the surgeon to avoid entering into the orbit and since medical management alone is unlikely to produce a positive result. In surgery, the use of an image-guidance system can also help to avoid complications.

Consent

Written informed consent was obtained from the patient for publication of this Case Report and any accompanying images. A copy of the written consent is available for review by the Editor-in-Chief of this journal.

Table 1 Types of maxillary sinus hypoplasia [23]

Maxillary sinus hypoplasia type	Characteristics
Type 1	Normal Uncinate. Defined infundibular passage
Type 2	Hypoplastic or absent uncinata. Opacified sinus
Type 3	Absent Uncinate. Profound hypoplasia of the sinus

Abbreviations

CMA: Chronic maxillary atelectasis; CRS: Chronic rhinosinusitis; CT: Computed tomography; MIW: Medial infundibular wall; MRI: Magnetic resonance imaging; MSA: Maxillary sinus atelectasis; MSH: Maxillary sinus hypoplasia; OMU: Ostiomeatal unit; SSS: Silent sinus syndrome.

Competing interests

JG serves on the editorial board for *Clinical and Molecular Allergy*. The authors declare no other conflicts of interest.

Authors' contributions

DG: conception and design; acquisition of data; analysis and interpretation of data; drafting the manuscript. PP: acquisition of data; drafting the manuscript. JG: analysis of data; revising the manuscript. All authors read and approved the final manuscript.

Acknowledgments

The authors thank Victoria L. Jackson, MLIS (Academic and Research Support, Mayo Clinic, Jacksonville, FL) for her assistance in the editing and preparation of this manuscript.

Author details

¹Department of Otolaryngology, Mayo Clinic, 4500 San Pablo Road, Jacksonville, FL 32224, USA. ²Department of Otorhinolaryngology, Mayo Clinic, 4500 San Pablo Road, Jacksonville, FL 32224, USA.

Received: 12 July 2013 Accepted: 23 November 2013

Published: 9 December 2013

References

1. Cobb AR, Murthy R, Cousin GC, El-Rasheed A, Toma A, Uddin J, Manisali M: **Silent sinus syndrome.** *Br J Oral Maxillofac Surg* 2011, **50**:e81–e85.
2. Montgomery WW: **Mucocele of the maxillary sinus causing enophthalmos.** *Eye Ear Nose Throat Mon* 1964, **43**:41–44.
3. Soparkar CN, Patrinely JR, Cuaycong MJ, Dailey RA, Kersten RC, Rubin PA, Linberg JV, Howard GR, Donovan DT, Matoba AY, et al: **The silent sinus syndrome. A cause of spontaneous enophthalmos.** *Ophthalmology* 1994, **101**:772–778.
4. Illner A, Davidson HC, Harnsberger HR, Hoffman J: **The silent sinus syndrome: clinical and radiographic findings.** *AJR Am J Roentgenol* 2002, **178**:503–506.
5. Habibi A, Sedaghat MR, Habibi M, Mellati E: **Silent sinus syndrome: report of a case.** *Oral Surg Oral Med Oral Pathol Oral Radiol Endod* 2008, **105**:e32–e35.
6. Rose G, Sandy C, Hallberg L, Moseley I: **Clinical and radiologic characteristics of the imploding antrum or "silent sinus" syndrome.** *Ophthalmology* 2003, **110**:811–818.
7. Buono LM: **The silent sinus syndrome: maxillary sinus atelectasis with enophthalmos and hypoglobus.** *Curr Opin Ophthalmol* 2004, **15**:486–489.
8. Monos T, Levy J, Lifshitz T, Puterman M: **The silent sinus syndrome.** *Isr Med Assoc J* 2005, **7**:333–335.
9. Annino D, Goguen L: **Silent sinus syndrome.** *Curr Opin Otolaryngol Head Neck Surg* 2008, **16**:22–25.
10. Baghat M, Bahgat Y, Bahgat A: **Silent sinus syndrome.** *BMJ Case Rep* 2012. 10.1136/bcr-2012-007198.
11. Brandt MG, Wright ED: **The silent sinus syndrome is a form of maxillary atelectasis: a systematic review of all reported cases.** *Am J Rhinol* 2008, **22**:68.
12. Sánchez-Dalmau BF, Pascual L, Lao X, Maiz J: **Sinus syndrome, an uncommon cause of enophthalmos.** *Arch Soc Esp Oftalmol* 2008, **83**:125–128.
13. Gaudino S, Lella GM, Piludu F, Martucci M, Schiarelli C, Africa E, Salvolini L, Colosimo C: **CT and MRI diagnosis of silent sinus syndrome.** *Radiol Med* 2012, **118**:265–275.
14. Sciarretta V, Pasquini E, Tesi F, Modugno GC, Farneti G: **Endoscopic sinus surgery for the treatment of maxillary sinus atelectasis and silent sinus syndrome.** *J Otolaryngol* 2006, **35**:60–64.
15. Nkenke E, Alexiou C, Iro H, Amann K, Kirchner T, Häusler G, Neukam FW, Holbach LM: **Management of spontaneous enophthalmos due to silent sinus syndrome: a case report.** *Int J Oral Maxillofac Surg* 2005, **34**:809–811.

16. Numa WA, Desai U, Gold DR, Heher KL, Annino DJ: **Silent sinus syndrome: a case presentation and comprehensive review of all 84 reported cases.** *Ann Otol Rhinol Laryngol* 2005, **114**:688–694.
17. Ferri A, Ferri Teore, Sesenna E: **Bilateral silent sinus syndrome: case report and surgical solution.** *J Oral Maxillofac Surg* 2012, **70**:103–106.
18. Borges P, Branco C, Subtil J: **Endonasal endoscopic repair of the orbital floor defect in the silent sinus syndrome.** *Otolaryngol Head Neck Surg* 2006, **135**:800–802.
19. Cardesin A, Eseamilla Y, Romera M, Molina JA: **Single surgical step for endoscopic surgery and orbital reconstruction of a silent sinus syndrome.** *Acta Otorrinolaringol Esp* 2013, **64**:297–299.
20. Chow AW, Benninger MS, Brook I, Brozek JL, Goldstein EJ, Hicks LA, Pankey GA, Seleznick M, Volturo G, Wald ER, File TM Jr: **Infectious diseases society of America: IDSA clinical practice guideline for acute bacterial rhinosinusitis in children and adults.** *Clin Infect Dis* 2012, **54**:e72–e112.
21. Hamilos DL: **Chronic rhinosinusitis: epidemiology and medical management.** *J Allergy Clin Immunol* 2011, **128**:693–707.
22. Bolger WE, Woodruff WW, Morehead J, Parsons DS: **Maxillary sinus hypoplasia: classification and description of associated uncinate process hypoplasia.** *Otolaryngol Head Neck Surg* 1990, **103**:759.
23. Erden T, Aktas D, Erden G, Miman MC, Ozturan O: **Maxillary sinus hypoplasia.** *Rhinology* 2002, **40**:150–153.
24. Kass ES, Salman S, Weber AL, Rubin PA, Montgomery WW: **Chronic maxillary atelectasis.** *Ann Oto Rhinol Laryngol* 1997, **106**:109–116.
25. Price D, Friedman O: **Facial asymmetry in maxillary sinus hypoplasia.** *Int J Pediatr Otorhinolaryngol* 2007, **71**:1627–1630.
26. Arikan OK, Onaran Z, Muluk NB, Yilmazbaş P, Yazici I: **Enophthalmos due to atelectasis of the maxillary sinus: silent sinus syndrome.** *J Craniofac Surg* 2009, **20**:2156–2159.
27. Vander Meer JB, Harris G, Toohill RJ, Smith TL: **The silent sinus syndrome: a case series and literature review.** *Laryngoscope* 2001, **111**:975–978.
28. Naik RM, Khemani S, Saleh HA: **Frontal silent sinus syndrome.** *Otolaryngol Head Neck Surg* 2013, **148**:354–355.
29. Jung D, Gray S: **Silent sinus syndrome after lateral fracture of the inferior turbinate.** *Otolaryngol Head Neck Surg* 2012, **146**:863–864.
30. Bossolesi P, Autelitano L, Brusati R, Castelnovo P: **The silent sinus syndrome: diagnosis and surgical treatment.** *Rhinology* 2008, **46**:308–316.

doi:10.1186/1476-7961-11-5

Cite this article as: Guillen et al.: The silent sinus syndrome: protean manifestations of a rare upper respiratory disorder revisited. *Clinical and Molecular Allergy* 2013 **11**:5.

Submit your next manuscript to BioMed Central and take full advantage of:

- Convenient online submission
- Thorough peer review
- No space constraints or color figure charges
- Immediate publication on acceptance
- Inclusion in PubMed, CAS, Scopus and Google Scholar
- Research which is freely available for redistribution

Submit your manuscript at
www.biomedcentral.com/submit

